



**BRUNO AZEVEDO**

# **CONE BEAM GUY**

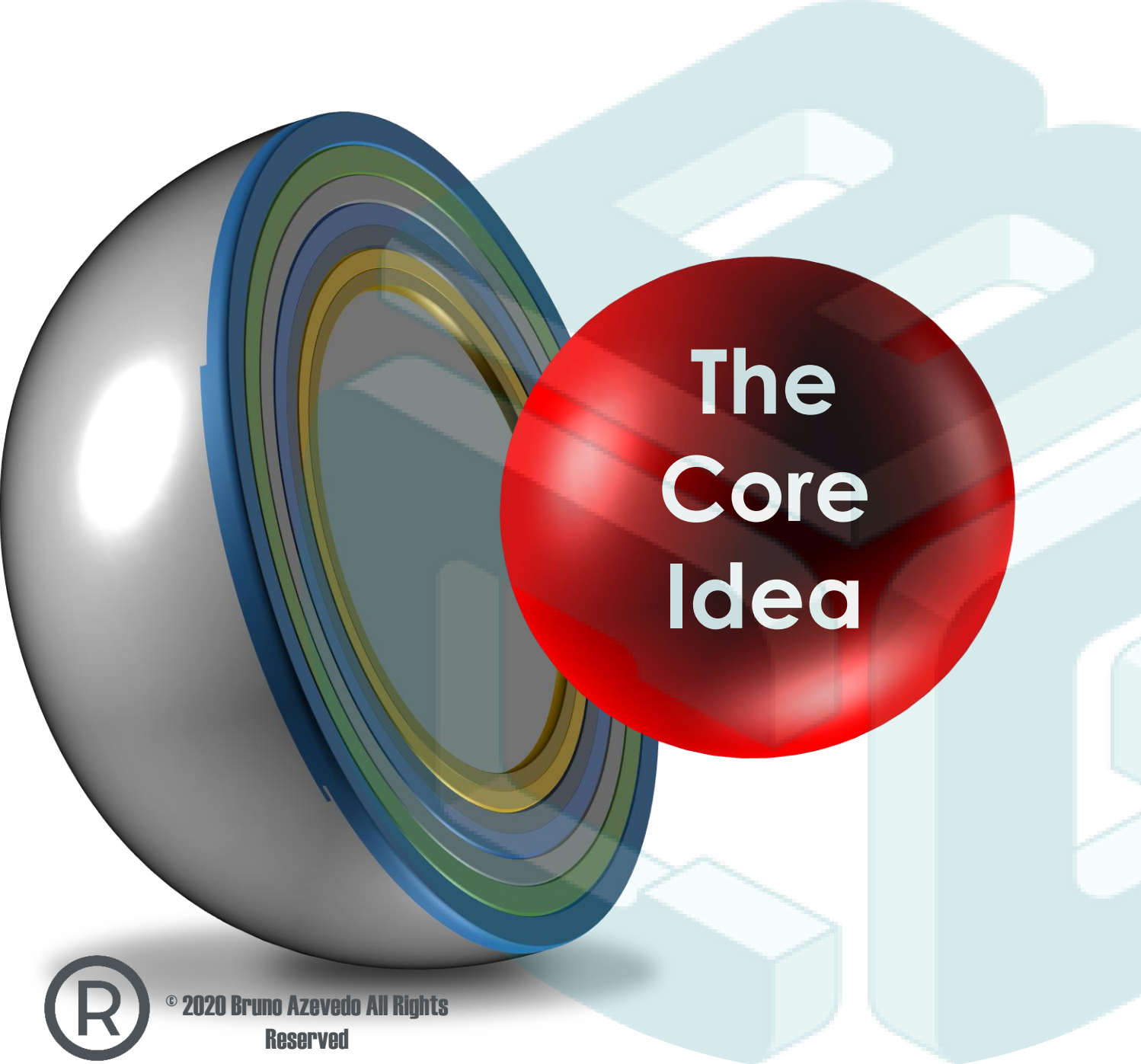
**PANORAMIC INTERPRETATION  
SEQUENCE AND IMAGING FINDINGS  
DESCRIPTION**





When reading a  
Panoramic Radiograph  
follow the Zones 1- 6





# The Core Idea

## Differential Diagnosis

The determination of which of two or more diseases with similar symptoms is the one from which the patient is suffering, by a systematic comparison and contrasting of the clinical findings.



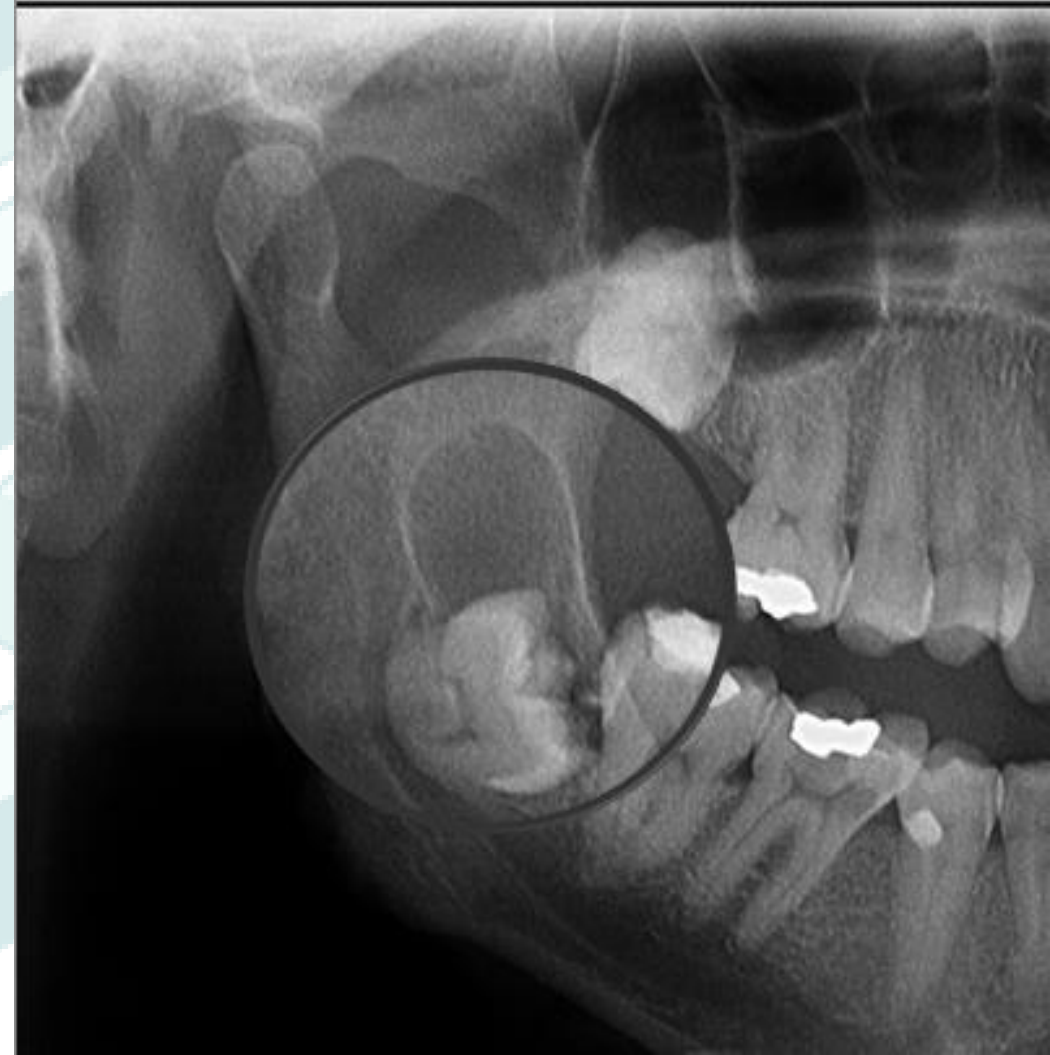


# Imaging Description

## I see.....



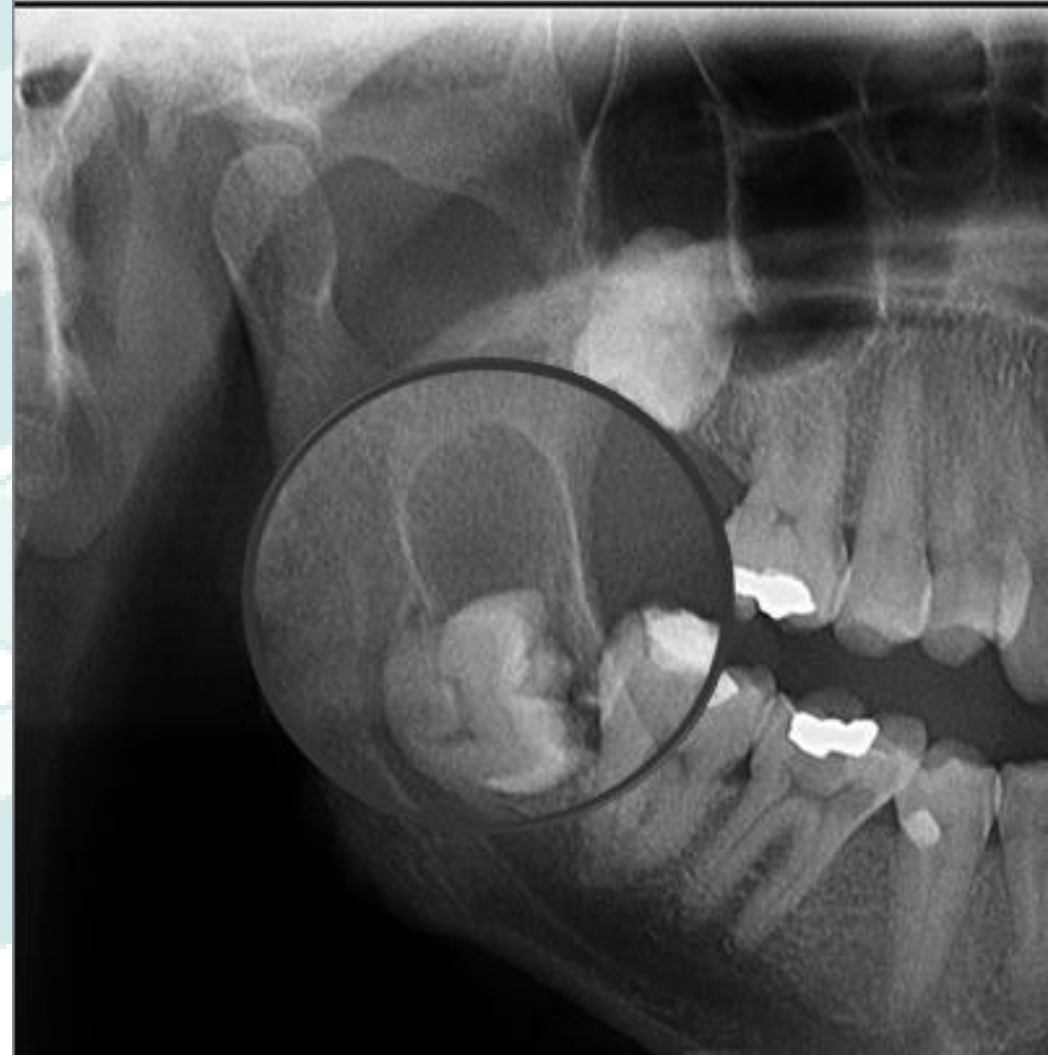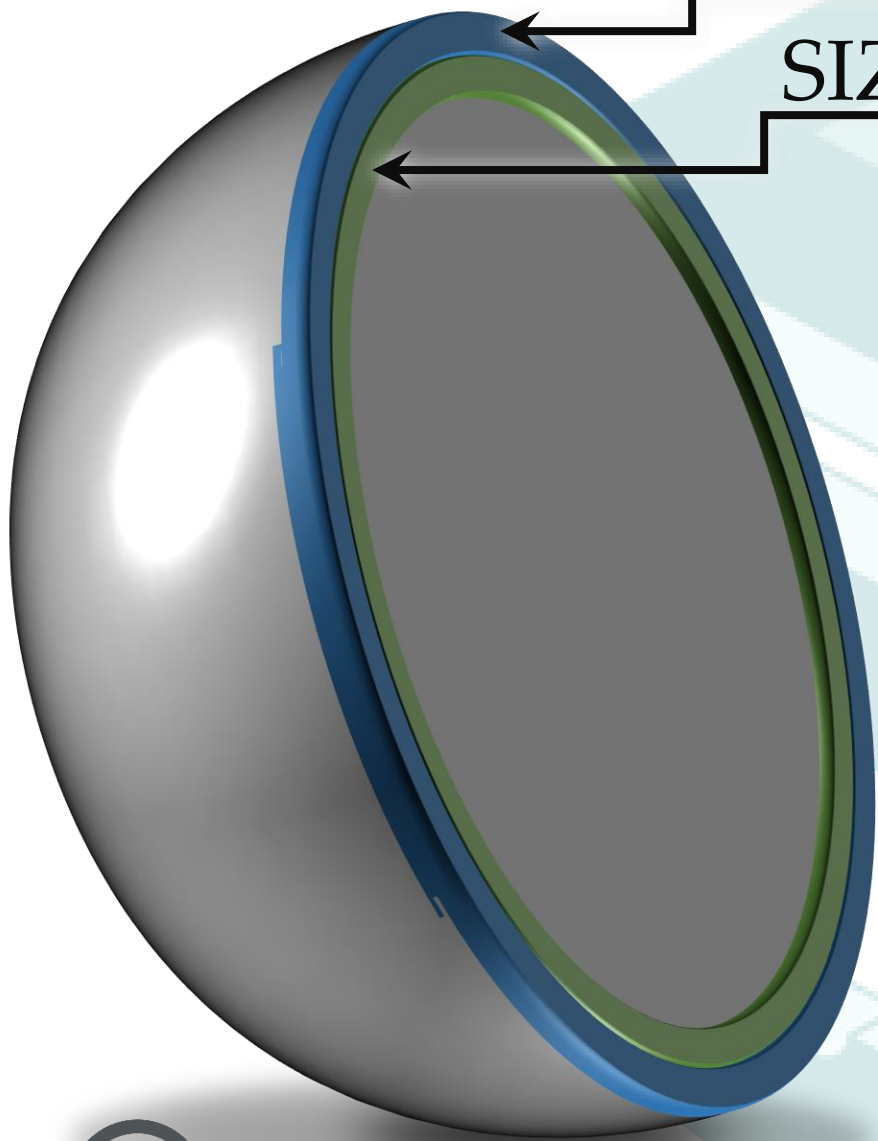
NUMBER



© 2020 Bruno Azevedo All Rights Reserved

NUMBER

SIZE

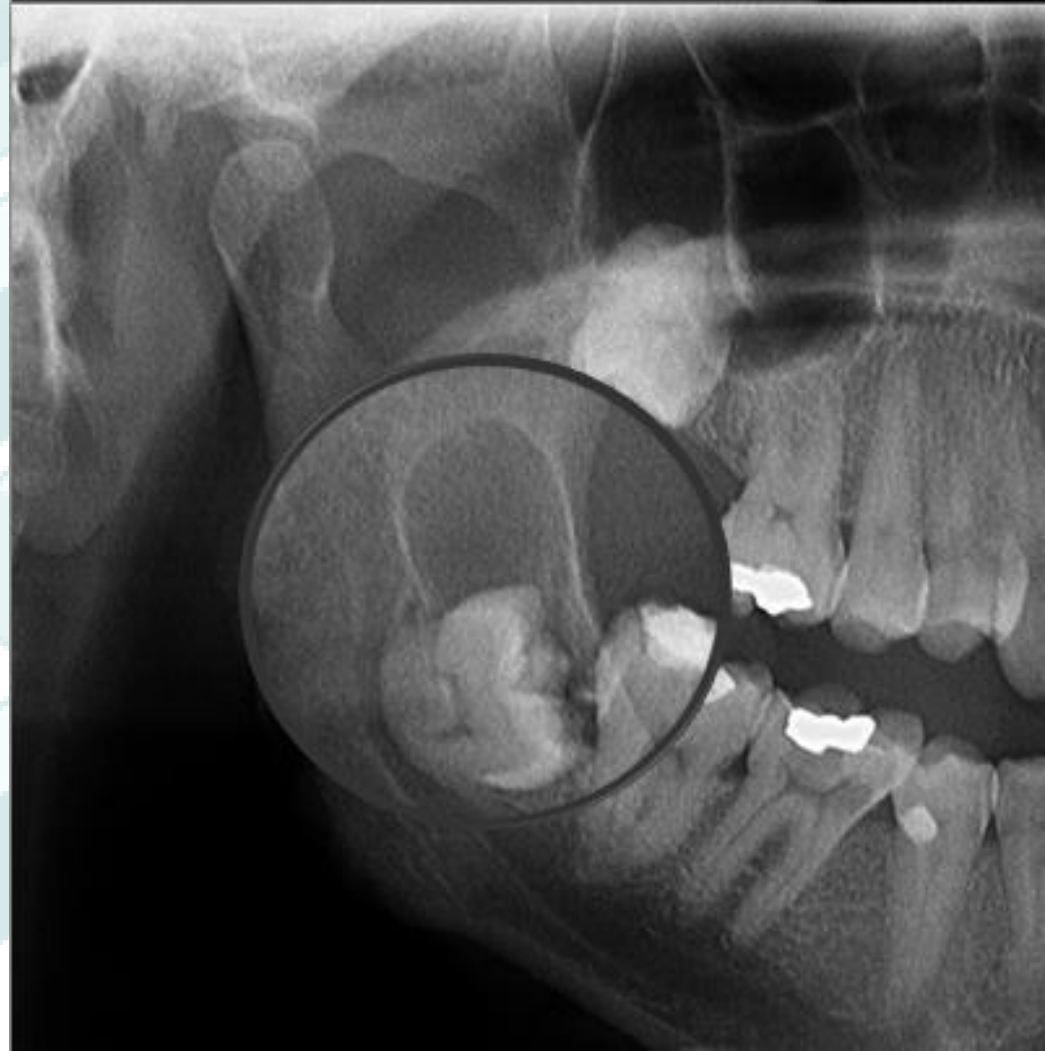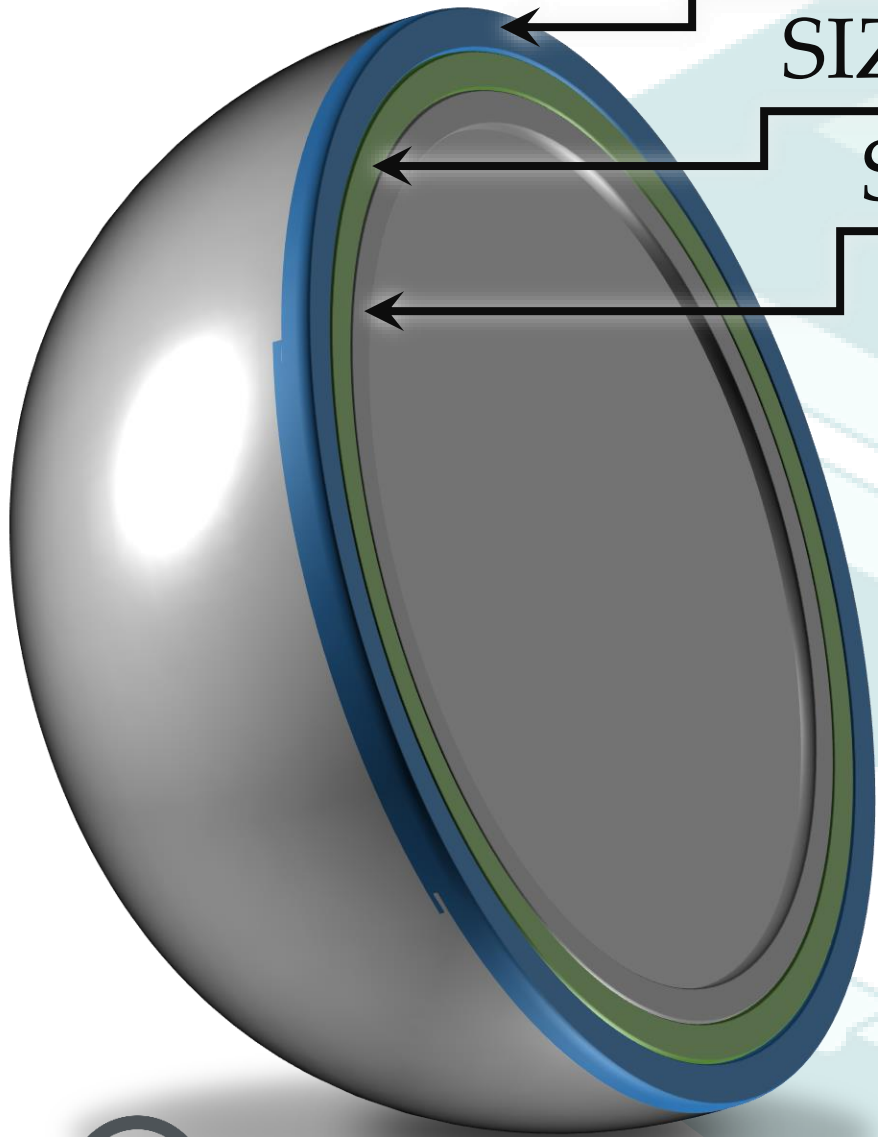


© 2020 Bruno Azevedo All Rights Reserved

NUMBER

SIZE

SHAPE - INTERNAL STRUCTURE

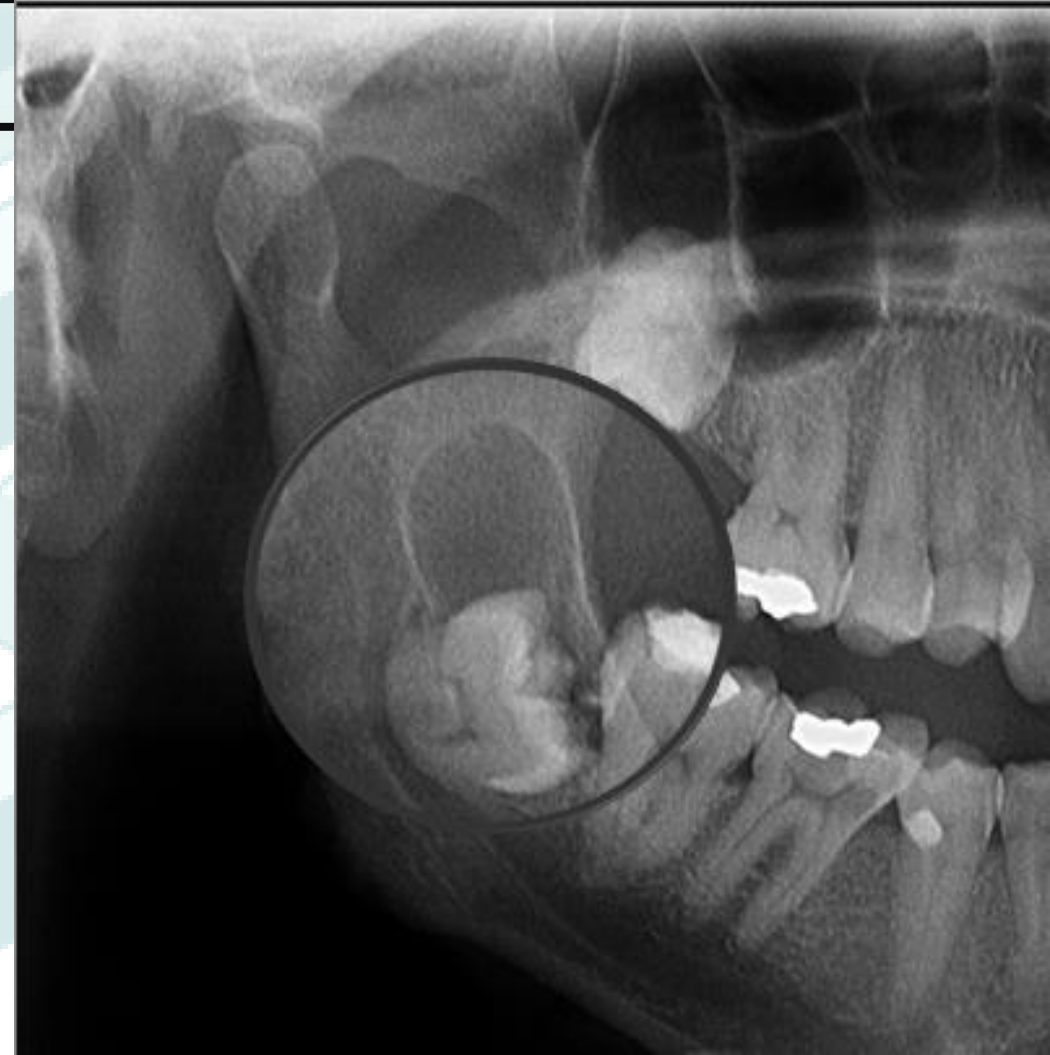
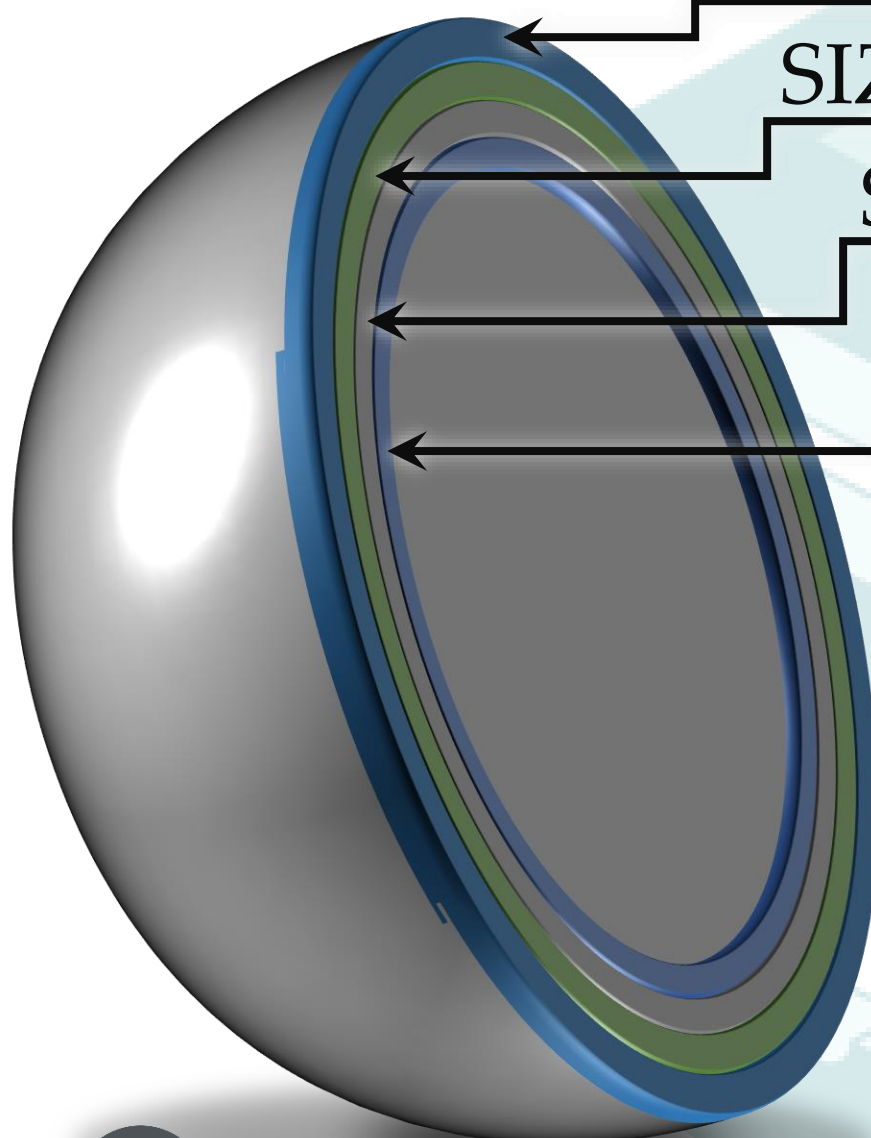


NUMBER

SIZE

SHAPE - INTERNAL STRUCTURE

PERIPHERY





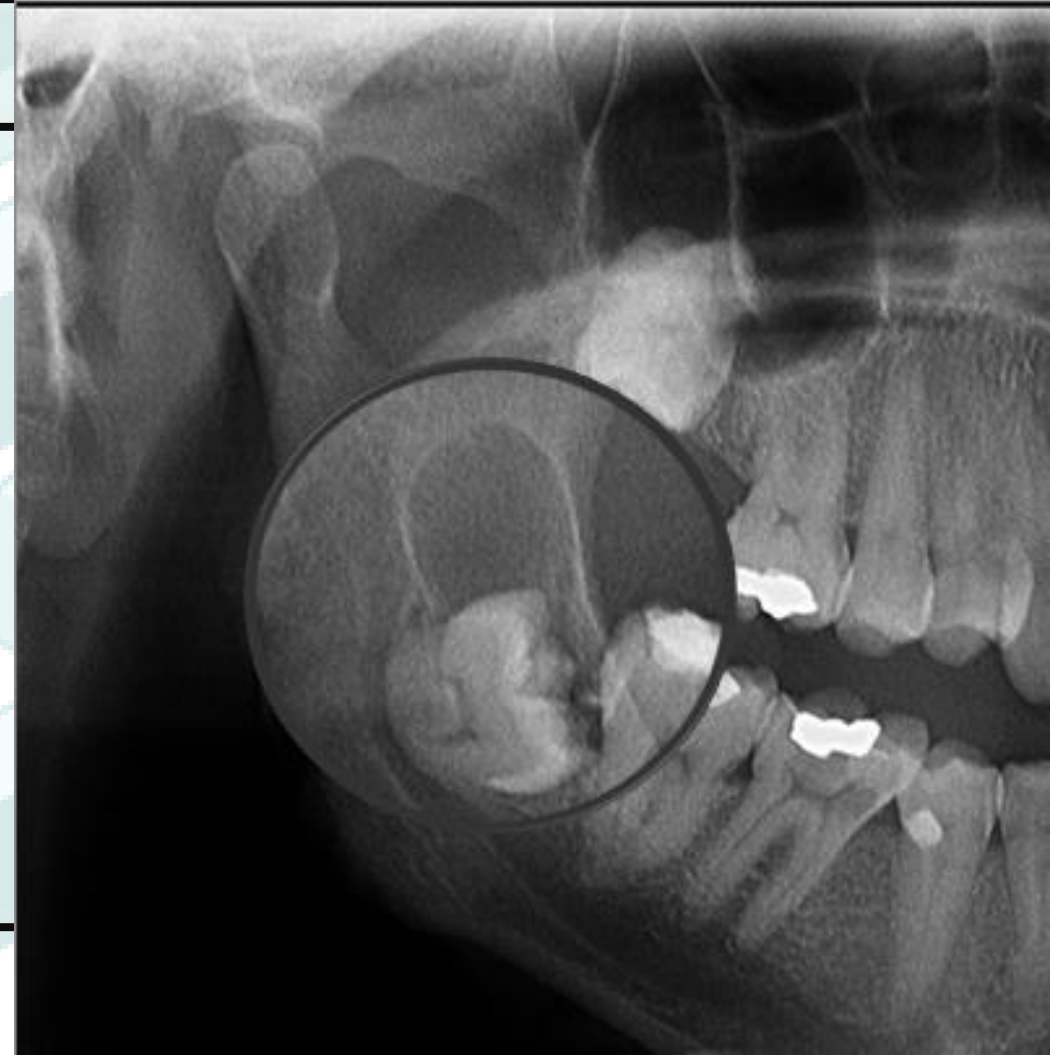
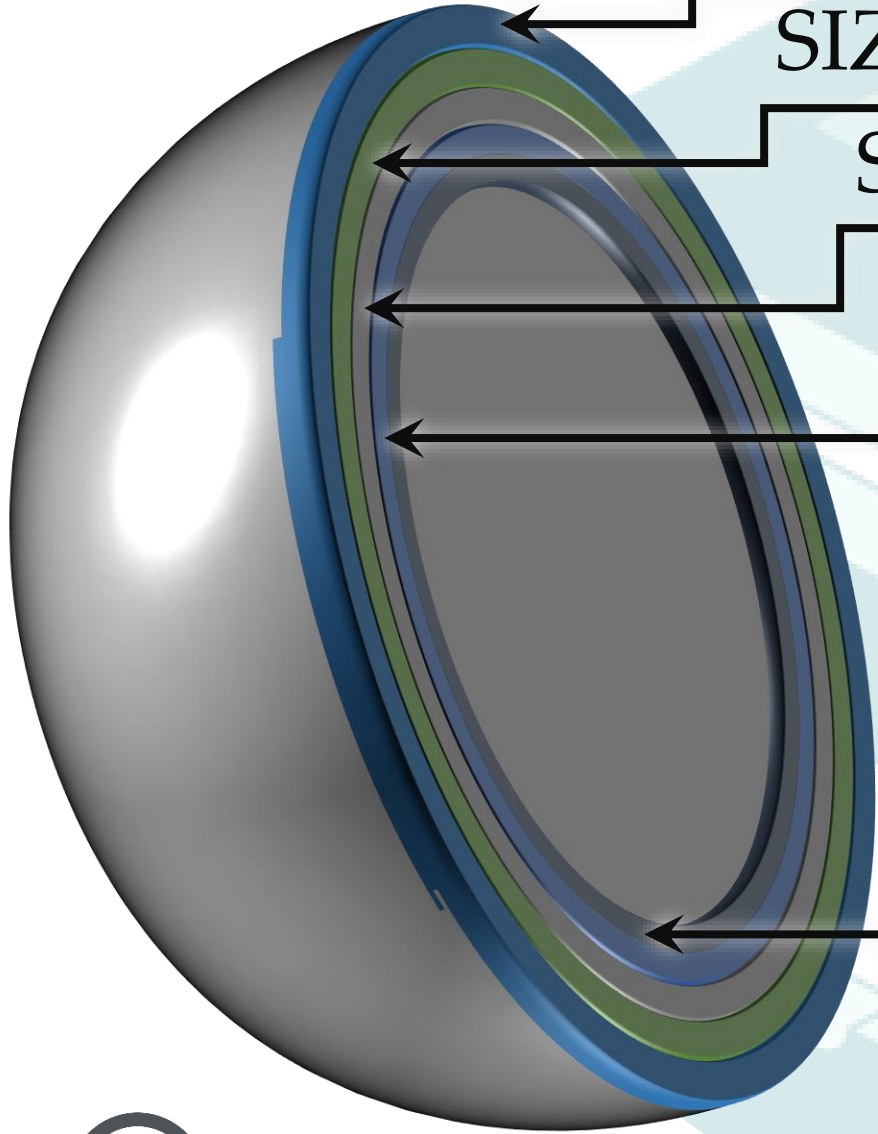
NUMBER

SIZE

SHAPE - INTERNAL STRUCTURE

PERIPHERY

DENSITY



NUMBER

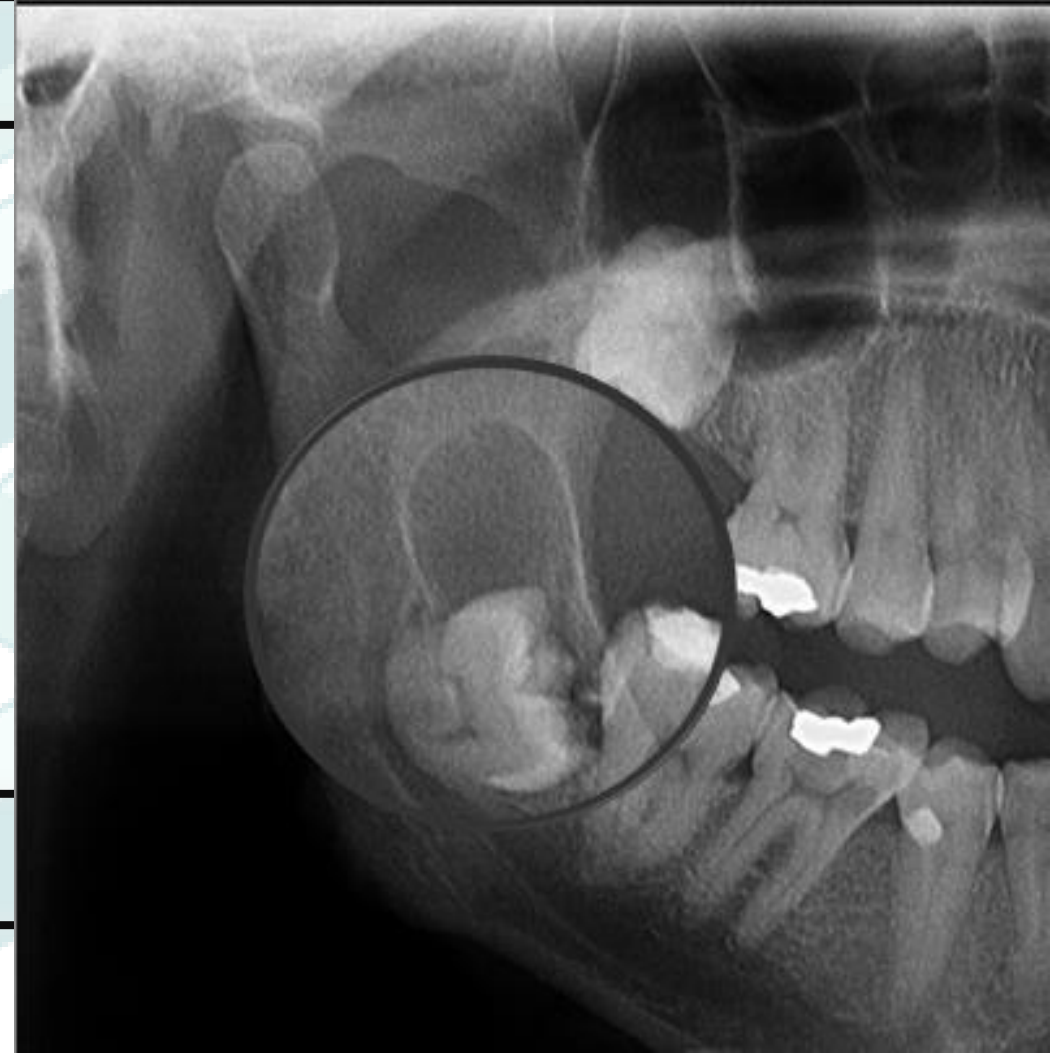
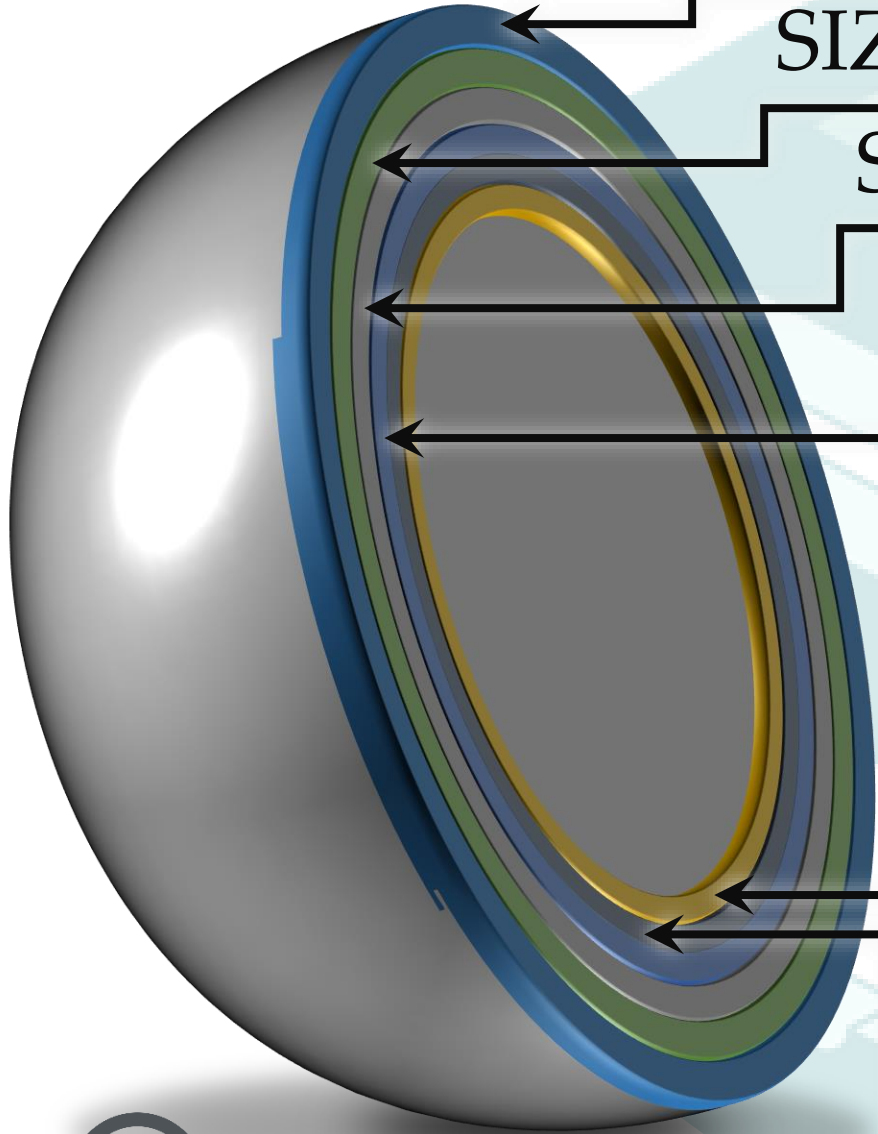
SIZE

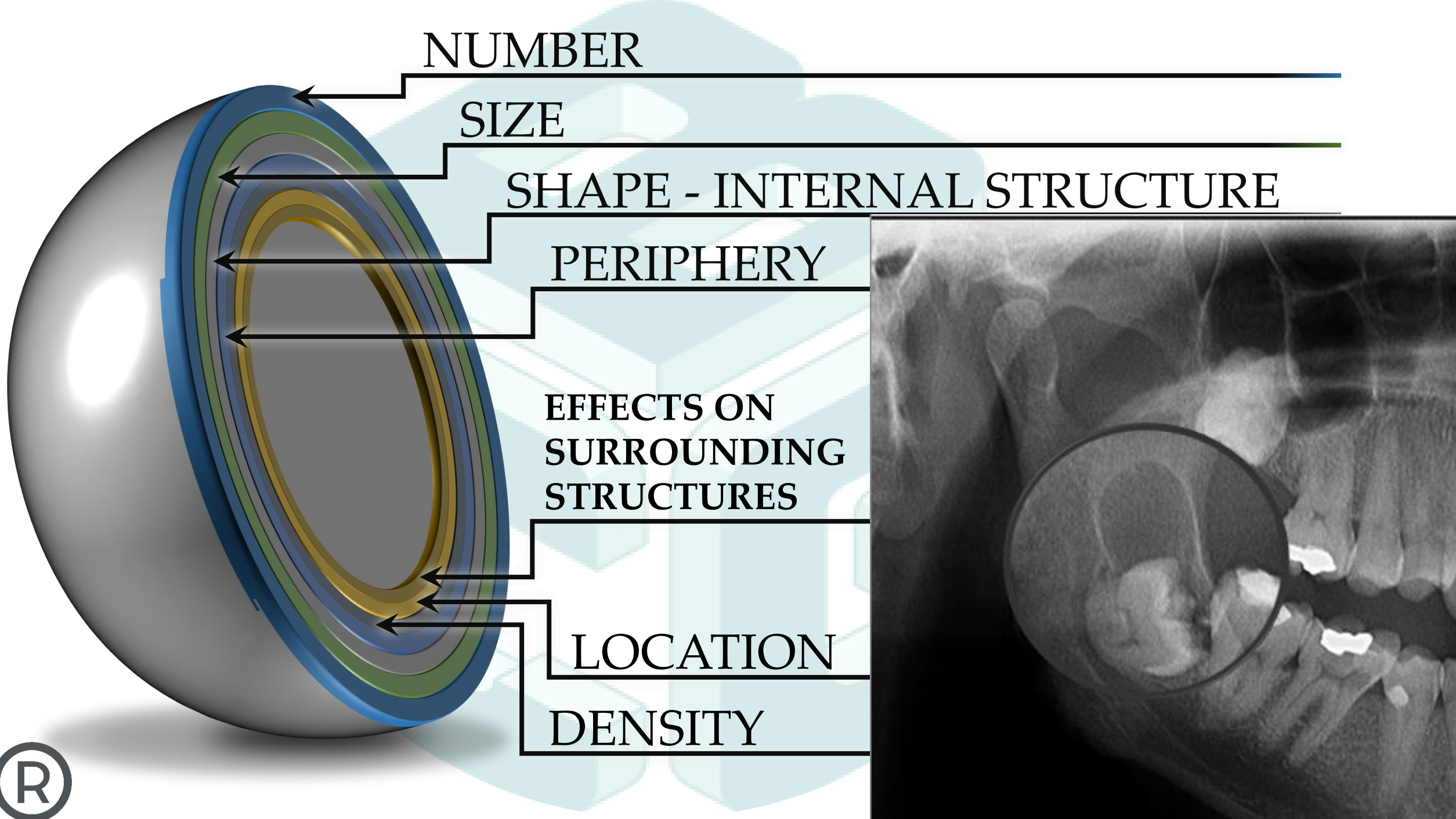
SHAPE - INTERNAL STRUCTURE

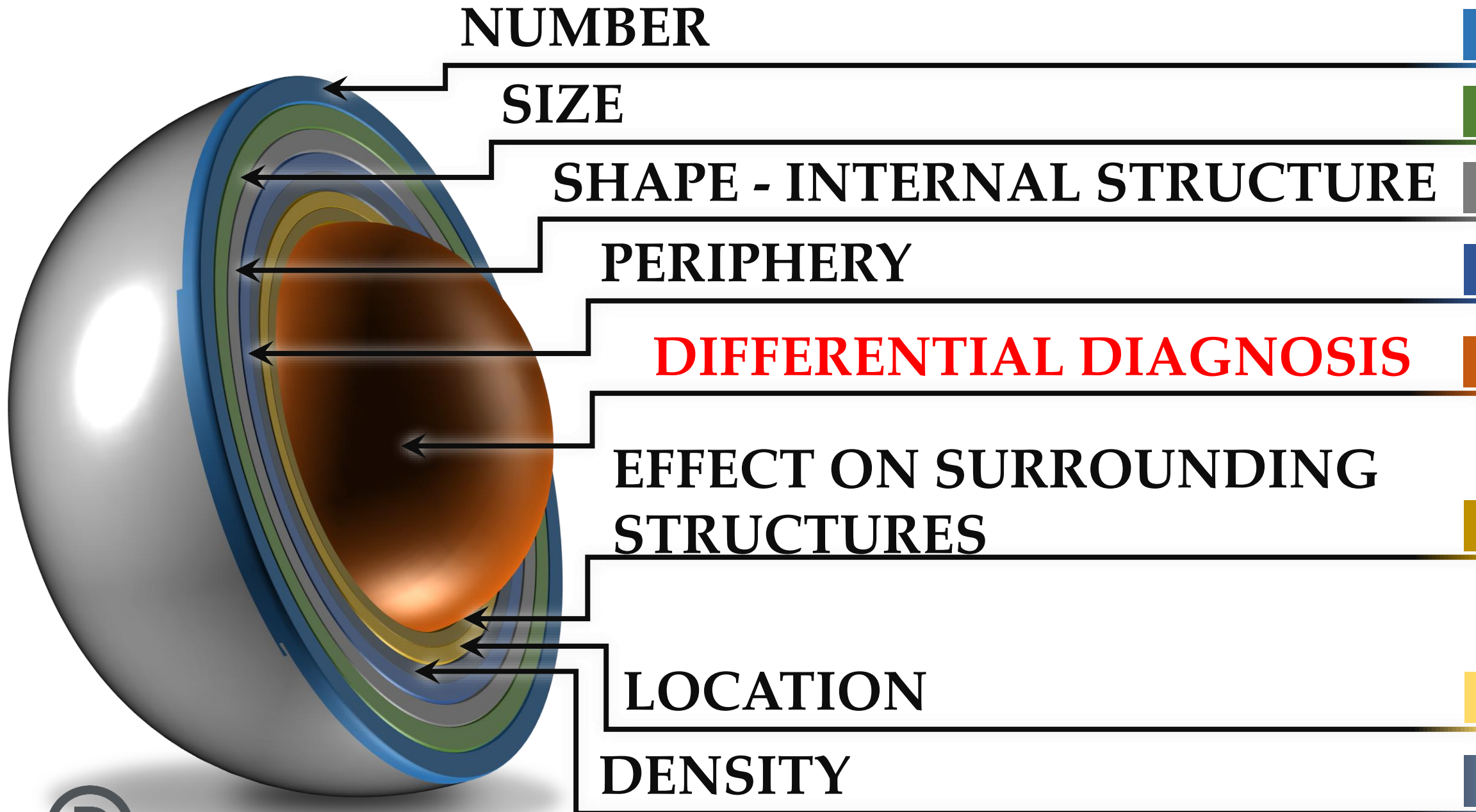
PERIPHERY

LOCATION

DENSITY










# Number

One

Two

Multiple





## Size

Small

Large

Measurements mm/cm

Use common sense





## Shape

Round

Ovoid

Triangular (TMJ)

Irregular

## Internal Structure

Multilocular

Scallop





# Periphery

Well Defined

Corticated

Non-Corticated

ill Defined







# Density


Radiolucent

Radiopaque

Mixed

Soft Tissue Density






# Location

Superior to  
Inferior to  
Distal to  
Mesial to  
Associated with  
Arising from  
In the area of #





## Effects on Surrounding Structures

Tooth Displacement  
Tooth Resorption  
Bone Expansion  
Bone Perforation  
Mandibular Canal  
Sinus Floor





[bruno@conebeamguy.com](mailto:bruno@conebeamguy.com)

[www.conebeamguy.com](http://www.conebeamguy.com)

#conebeamguy

